

Fungal granuloma of the nose in an African male: a case report

Oyewole EA *FMCORL*¹, Agboola AOJ *MBChB*², Banjo AAF *FMCPATH*³, Deji-Agboola AM *MSc*⁴

¹Olabisi Onabanjo University, Department of Surgery, Ear, Nose and Throat Unit, Sagamu

²Olabisi Onabanjo University, Department of Morbid Anatomy, Sagamu

³Lagos University Teaching Hospital, Department of Morbid Anatomy, Idi-Araba

⁴Olabisi Onabanjo University, Department of Medical Microbiology and Parasitology, Sagamu

Corresponding Author: Oyewole EA yomyeh@yahoo.com

Abstract

Chronic fungal infection of the nose and paranasal sinuses is relatively rare and often difficult to treat. Very few cases have been reported from Nigeria till lately. This is a clinical case report of a 46-year-old Nigerian male who presented with a right nasal mass after being treated for allergic chronic sinusitis for over 10 years. Excision biopsy of the mass revealed a fungal granuloma and mycotic culture reported as *Aspergillus fumigatus*. Chronic fungal infection of the nose and paranasal sinuses should be considered when patients are not responding satisfactorily to routine management of chronic rhino sinusitis.

KEY WORDS: Fungus, *Aspergillus*, Chronic sinusitis, Mycetoma.

Introduction

Mycotic infection of the nose and paranasal sinuses can be caused by various fungi, which include *Aspergillus* spp, *Phycomycetes*, *Candida* spp and *Rhinosporidium* spp etc. The commonest fungal infection of the nose and sinuses is believed to be caused by *Aspergillus*, (Stainberger et al 1984).

Although fungal infection of the nose and sinuses may occur in healthy people, it is usually seen in immuno-compromised and debilitated patients. The clinical features include nasal obstruction, rhinorrhoea, epistaxis, proptosis and facial swelling. Various clinical forms of fungal infection of the nose have been described as allergic, non-invasive, invasive or fulminant (Mackay and Bull 1997).

The first case of chronic fungal infection of the nose from Nigeria was reported in 1959 (Martinson 1963). Since then various forms of the disease have been reported (Nwana et al 1988, Ashiru et al 1996, Lasisi et al 1997, Ezeanolue and Odike 2004). This is a case report of fungal granuloma of the nose in what appears to be a progression from the allergic to the invasive type over a period of 15 years.

Case Report

A 46-year-old male trader who had been living in the western part of Nigeria all his life, presented at the Ear, Nose and Throat Clinic of the Olabisi Onabanjo University Teaching Hospital, Sagamu Nigeria with a history of persistent right nasal blockage of 8 months duration, right nasal swelling of 6 months duration and upper lip swelling of 3 months duration. There was an episode of epistaxis of about 3 weeks duration before presentation and the patient denied any history of trauma to the face.

He had been treated for 'catarrh' at another hospital for over 10 years and during the course of this treatment he had received three sessions of antral wash-out. However, he absconded from treatment five years ago when he was offered a nasal surgery under general anesthesia, in the same hospital. Since then he had been taking various forms of medication prescribed by self and chemists with partial relief from time to time. The medications include Actifed, Piriton, Prednisolone and Otrivine nose drops.

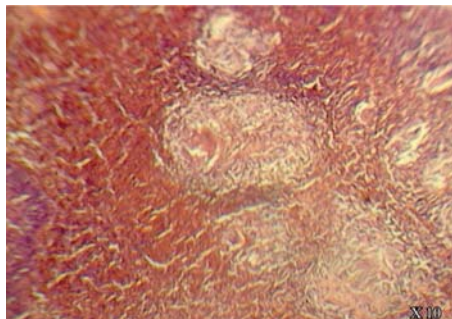
Examination of the nose revealed a firm mass on the lateral wall of the right nasal vestibule extending to the inferior turbinate (Fig. 1).

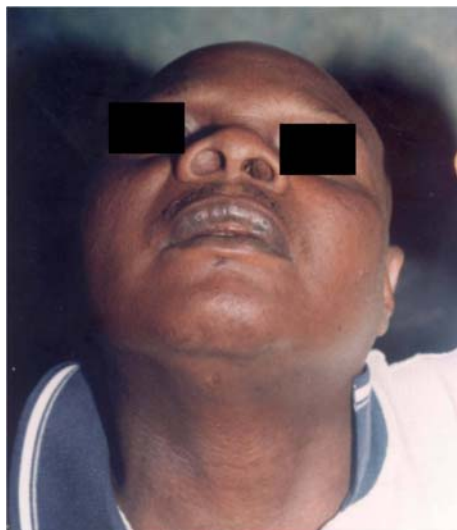

Figure 1: Observe the mass in the right nasal cavity

A X-ray of the paranasal sinuses showed bilateral maxillary antral haziness and an enlarged right inferior turbinate. A CT scan was not done because it was not readily available and unaffordable to the patient. A diagnosis of chronic sinusitis, scleroderma, to rule out benign tumour of the nose was made and an excision biopsy of the mass and right intranasal anastomy was performed. Findings at the operation were a scirrhous mass on the lateral wall of the right nasal vestibule extending to the inferior turbinate and involving the ala cartilage, which made complete excision impossible. The histopathology report revealed fungal granuloma (Fig. 2).

Figure 2: Micrograph showing fungal granuloma of the excised mass from the right nasal vestibule.

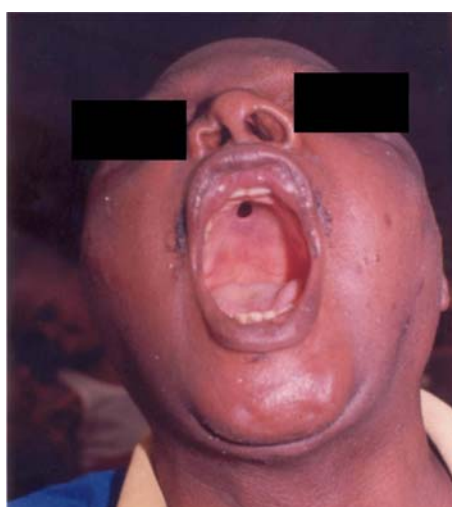

Microbiological diagnosis was not possible with the same specimen so a scraping of the right nasal vestibule was sent for mycology a few weeks afterwards, but there was no growth. The patient was screened for retroviral infection, which was negative for both HIV 1&11 (western blot).

His fasting blood sugar was 91 mg/dl. He was commenced on oral ketoconazole and topical clotrimazole; however, the patient could not afford to buy his drugs regularly and often missed his appointments.

Three months post excision biopsy he presented with nasal speech and regurgitation of fluid through the nose and four months after he developed an oro-nasal fistula (Fig. 3)

Figure 3: Perforation of the anterior aspect of the hard palate.



A nasal swab was taken for mycotic study with a report of heavy growth of *Aspergillus Fumigatus*. The treatment was changed to oral fluconazole (Diflucan) and douching with miconazole (Daktarin) cream. He improved on this treatment, thereafter he had surgical closure of the oro-nasal fistula.

Discussion

Fungal infection of the nose and paranasal sinuses is relatively rare and often runs a chronic course. However it is believed to be almost endemic in parts of Sudan and Saudi Arabia (Kameswaren et al 1992). A relative increase in the number of new cases was recently reported from part of Nigeria (Lasisi et al 1997). It is usually caused by fungi such as *Aspergillus* spp, *Candida* spp, and *Phycomycetes*.

The mode of infection in nasal mycosis is not well understood but it has been suggested that implantation of fungus by insects, contamination from vegetation and inoculation from patients' fingernails could be some of the possible means (Martinson 1983).

Predisposing factors for fungal infection in the nose and paranasal sinuses include immunosuppressant, extensive antibiotic use or abuse resulting in suppression of normal bacterial flora of the nose with consequent opportunistic fungal infection and debilitating diseases (Lasisi et al 1997). The patient presented did not have any evidence of immunosuppressive nor debilitating disease. However, antibiotic abuse cannot be ruled out because it is readily available from so-called chemists without prescriptions.

Mucosal swelling and sinus obstruction, as seen in allergic rhino sinusitis, has also been implicated as predisposing factor in fungal infection of the nose (Bassiouny et al 1982). This patient was on treatment for chronic sinusitis for over 15 years with various forms of medications and 3 episodes of antral wash-out. The use of the steroid Prednisolone, as part of the treatment of his allergic condition, could also be a predisposing factor. Nevertheless, use of large doses of Prednisolone is one of the treatment options in the management of pulmonary aspergillosis (Shah 1998). It is also possible that this patient has had a form of fungal allergic rhino sinusitis from the onset, which is a recognized form of *Aspergillus* infection of the nose and paranasal sinuses (Mackay and Bull 1997).

The treatment of mycotic infection of the nose with antimycotics like Trichomycin Tm, Flucytosine Tm and Miconazole Tm is believed to be effective but relatively expensive (Lasisi et al 1997). Our patient was treated with oral Ketacomazole^Z (Nizoral and topical Clotrimazole (Canasten^R) initially which was later changed to fluconazole and miconazole tablets and cream respectively. The patient responded well to treatment and had successful surgical closure of the oro-nasal fistula. It had been reported that it is possible to treat patients with paranasal sinus mycetomas by functional endoscopic sinus surgery (FESS) alone without any medical adjuvant (Klossek et al 1997).

In conclusion clinical diagnosis of fungal infection of the nose poses a very serious challenge since the features are not clear-cut and the course of the disease is rather insidious. A high index of suspicion is required to make an early diagnosis of the condition. Patients on treatment for chronic allergic rhino sinusitis may benefit from mycotic studies especially when on steroids. The invasive form of fungal disease of the nose and sinuses may mimic a malignant condition. Ignorance and poverty is still a very major factor in patient management in the tropics.

References

- Ashiru JO, Ijaduola GTA, Aghadiuno PU, Adeyemi FA, Akang EE U (1996) Rhinosporidium: Case Report. East African Medical Journal 73: 414-415.
- Bassiouny A, Maher AB, Bucci T J, Moawad MK, Hendawy DS (1982) Non-invasive antrromycosis. Journal of Laryngology and Otology 96: 215-227.
- Ezeanolue BC, Odike MAC (2004) Nasal rhinosporidiosis – a case report and outcome of therapy with Fluconazole. Nigerian Journal of Otorhinolaryngology 1: 22-24.
- Kameswaren M, Al-Wadel A, Khurana P, Okafor BC (1992) Rhinocerebral aspergillosis. Journal of Laryngology and Otology. 106:981-985.
- Klossek JM, Serrano E, Peloquin L, Percodani J, Fontanel JP, Pessey JJ. (1997) Functional endoscopic sinus surgery and 109 mycetomas of paranasal sinuses. Laryngoscope 107: 112-117.
- Lasisi OA, Nwarogu OG, Akang E U (1997) Sinus mycosis - a case of persistent chronic sinusitis (case report). Nigerian Journal of Surgery 4: 77-80.
- Mackay IS, Bull TR (1997) Rhinology, p39–49, in: Kerr AG (1997) *Scott-Brown's Otolaryngology*, Vol 4. Butterworth Heinemann, Oxford.
- Martinson FD (1963) Rhinophycomycoses. Journal of Laryngology and Otology 77: 69-70.
- Martinson FD (1983) Zygomycosis in otorhinolaryngology practice. Advances in Otorhinolaryngology 29: 224-230.
- Nwana ETC, da Lilly-Tariah OB (1988) Rhinosporidiosis in the nasal cavity. Tropical Doctor 28:109-110.
- Shah A (1998) Allergic bronchopulmonary aspergillosis: A clinical review. Nigerian Medical Practitioner 36: 1-2.
- Stammberger H, Jaske R, Beaufort F (1984) Aspergillosis of the paranasal sinuses, X-ray diagnosis, histopathology of clinical aspects. Annals of Otology, Rhinology and Laryngology 93: 251-256.